



The Effect of Visceral Manipulation on Diastasis Recti Abdominis (DRA): A Case Series

Brandi Kirk, PT, CVTP, PRPC; Teri Elliott-Burke, PT, MHS, WCS, PRPC, CCB-PMD



Introduction

Diastasis Recti Abdominis (DRA) occurs frequently during pregnancy (66%¹ – 100%²) and immediately post partum (85%³) and 6 months postpartum (35-39%²). The abdominal musculature has been shown to play a role in posture, trunk and pelvic stability, respiration, trunk movement and support of the abdominal viscera. The occurrence of a DRA puts these functions in jeopardy.

A wide variety of treatment techniques, with therapeutic exercise being the primary one, have been reported to address DRA. The use of visceral manipulation has been reported, but not well defined.⁵

The retrospective review of 3 case studies reveals the positive impact of visceral manipulation, specifically the release of the mesenteric root of the jejunioleum, to resolve the DRA.

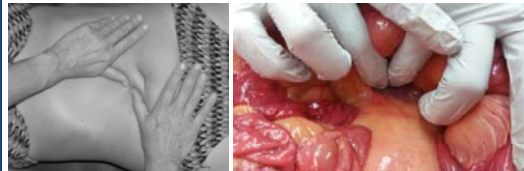
Description of Cases

Three women ages 33 to 39 years old with DRA. DRA was measured by figure width. Two of the three cases presented with thoracic pain, lumbar pain and constipation. One case presented with pelvic pain.

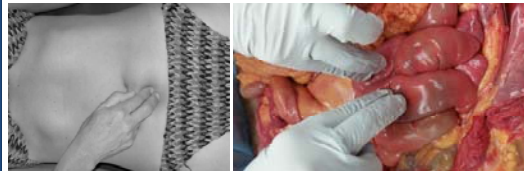
- Case 1 was G2P2 with first birth C-Section and second VBAC
- Case 2 was G2P2 with second degree tear with first child
- Case 3 was G2P2 with greater than 40 hours of labor with first birth

Interventions: 4 Techniques of the Jejunioleum as taught by the Barral Institute

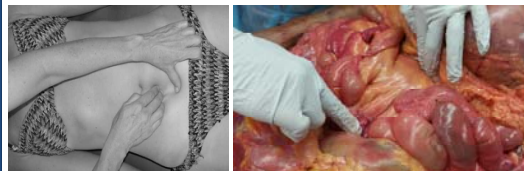Mobilizing Mesenteric Root



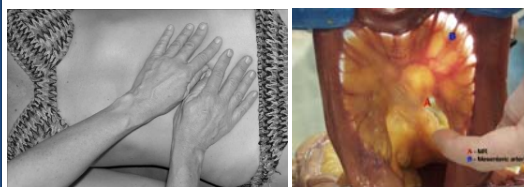
Mobilizing the Loops



Mobilizing the Mesentery



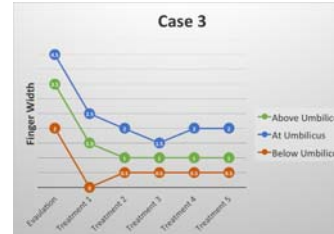
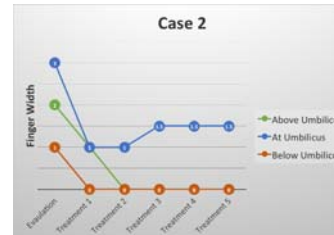
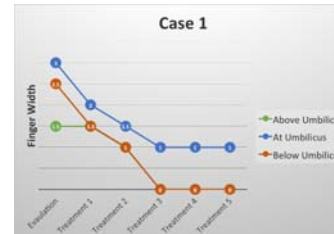
Motility



The authors wish to thank individuals who donate their bodies and tissues for the advancement of education and research.

University of California, Davis
College of Osteopathic Medicine of the Pacific (COMP)-Northwest
Western University of Health Sciences

Results: DRA Measurements



Results: Symptom Changes

Case 1 LBP decreased from 2-4/10 to 0/10. Right lumbar side bending increased from 5% to 100%. Function: care for children without back pain or difficulties.

Case 2 Bladder improved emptying, nocturia decreased from 1-0, eliminated post-void residual. Bowel improved from 1x every 4-5 days to daily (use of Miralax). Function: able to carry baby with no pain.

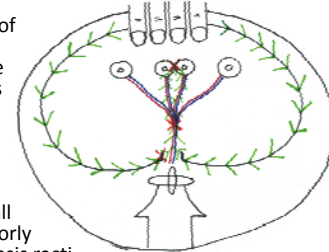
Case 3 LBP and sharp abdominal pain decreased from 5/10 to 0/10. Lumbar AROM increased from flexion 50% to 100% and extension from 70% to 80%. Function: can lift, carry, bend or front carry baby with no pain.

Discussion: Anatomy

- **Parietal Peritoneum** – a serous membrane; secretes serous fluid that lubricates organs. There are organs/structures that are intraperitoneal (inside the peritoneum) and organs/structures that are retroperitoneal (outside the peritoneum).
- **Mesenteric Root of the Jejunioleum** – a thickening of the parietal peritoneum from the ileocecal valve (ICV) to the duodenojejunal (DJ) junction; anterior to the abdominal aorta and inferior vena cava; provides a protected space for the mesenteric artery and vein to travel anteriorly.
- **Mesentery** – a continuation of the parietal peritoneum; like a sling that allows movement and attaches the organs to the posterior wall. The mesentery encases the mesenteric artery and vein and it wraps around the loops of the jejunioleum.

Discussion: Theory

- In cadaver dissections it is clear that the abdominal layers are not separate from each other. Each layer is attached to the layer posterior to it. The parietal peritoneum is the inner most layer.
- Since the mesenteric root of the jejunioleum and the jejunioleum mesentery are the most posterior aspects of the parietal peritoneum and if there is a restriction anywhere along these structures, then those restrictions would pull all the anterior abdominal wall layers laterally and posteriorly and thus causing the diastasis recti.



Conclusion

3 sessions of visceral manipulation to jejunioleum was effective in resolving 3 DRAs, which remained stable for 6-11 months

References

1. Boissonnault JS, Blaschak, MJ. Incidence of diastasis recti abdominis during the childbearing year. *Phys Ther* 1988;68:1082-1086.
2. Goncalves P, da Mota F, Brites AG, Pascoal A, Andrade AI, Carita D, Bo K. Prevalence and risk factors of diastasis recti abdominis from late pregnancy to 6 months postpartum, and relationship with lumbo-pelvic pain. *Man Ther* 2015;20:200-205.
3. Bursch SG. Interrater reliability of diastasis recti abdominis measurement. *Phys Ther* 1987;67:1077-1079.
4. Lee DG, Lee LJ, McLaughlin L. Stability, continence and breathing: the role of fascia following pregnancy and delivery. *J Bodywork Move Ther* 2008; 12:333-348.
5. Keeler J, Albrecht M, Eberhart L, Horn L, Donnelly C, Lowe D. Diastasis recti abdominis: a survey of women's health specialists for current physical therapy clinical practice for postpartum women. *J Section Women's Health* 2012;36:131-142.